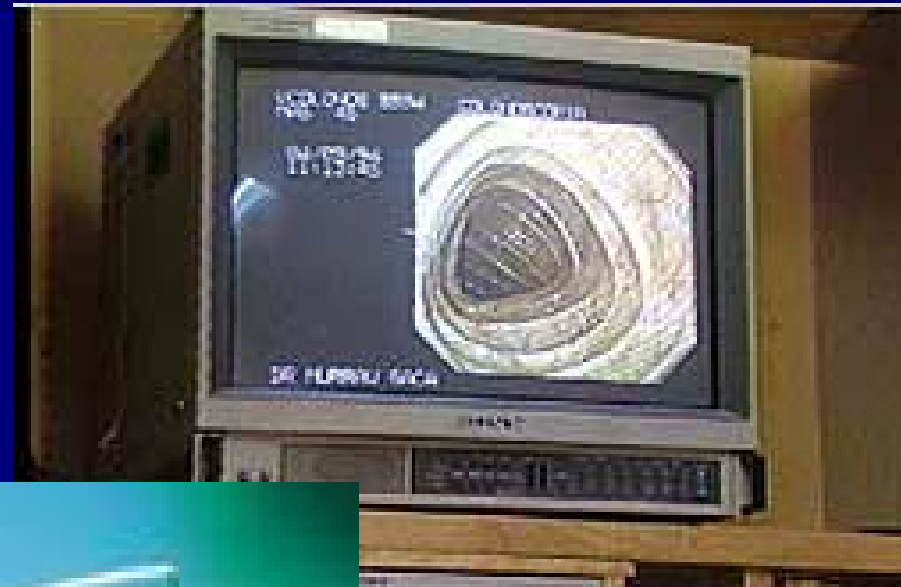


Procedural Gastroenterology: A Brief Overview

DR SANDIP PAL MD DM
Gastroenterologist and Hepatologist
NH, RN Tagore hospital



Tools of the trade



Gastrointestinal bleeding

- Culprit lesions

- Esophageal varices

- Banding

- Peptic ulcer

- Injection

- Heater probe

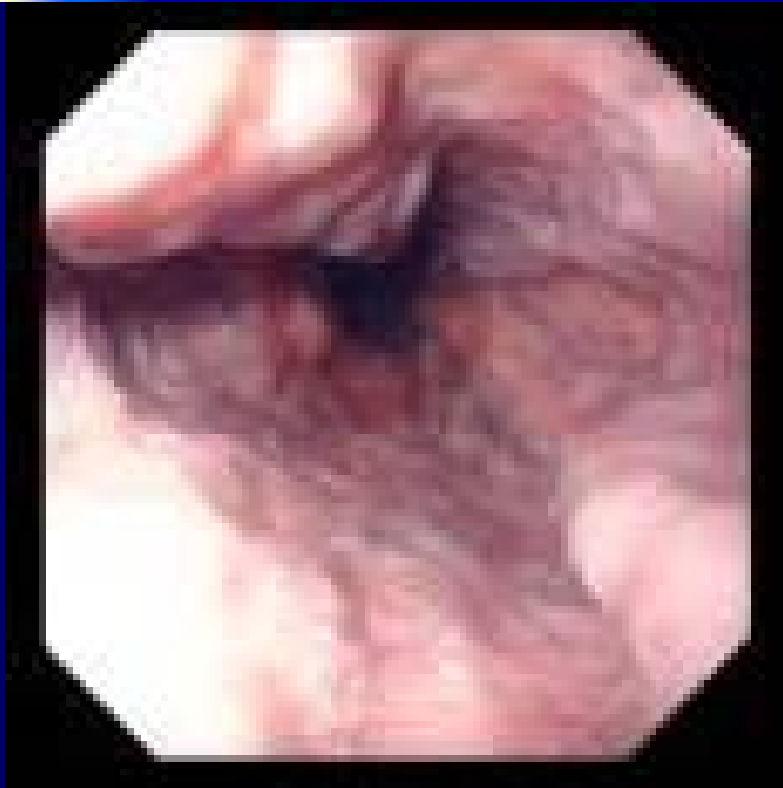
- Clipping

- Malignancy

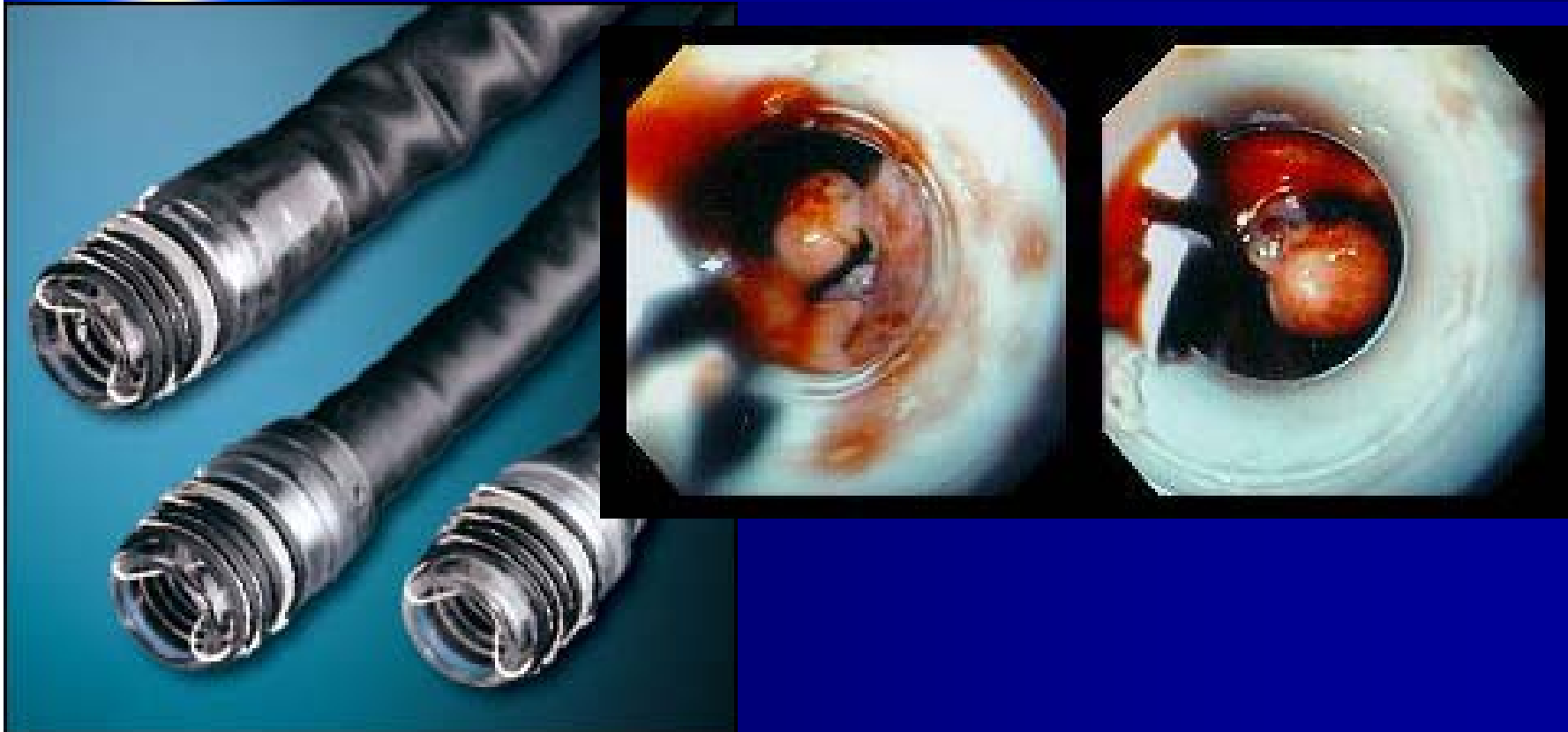
- Angiodysplasia

- Gastric antral vascular ectasia

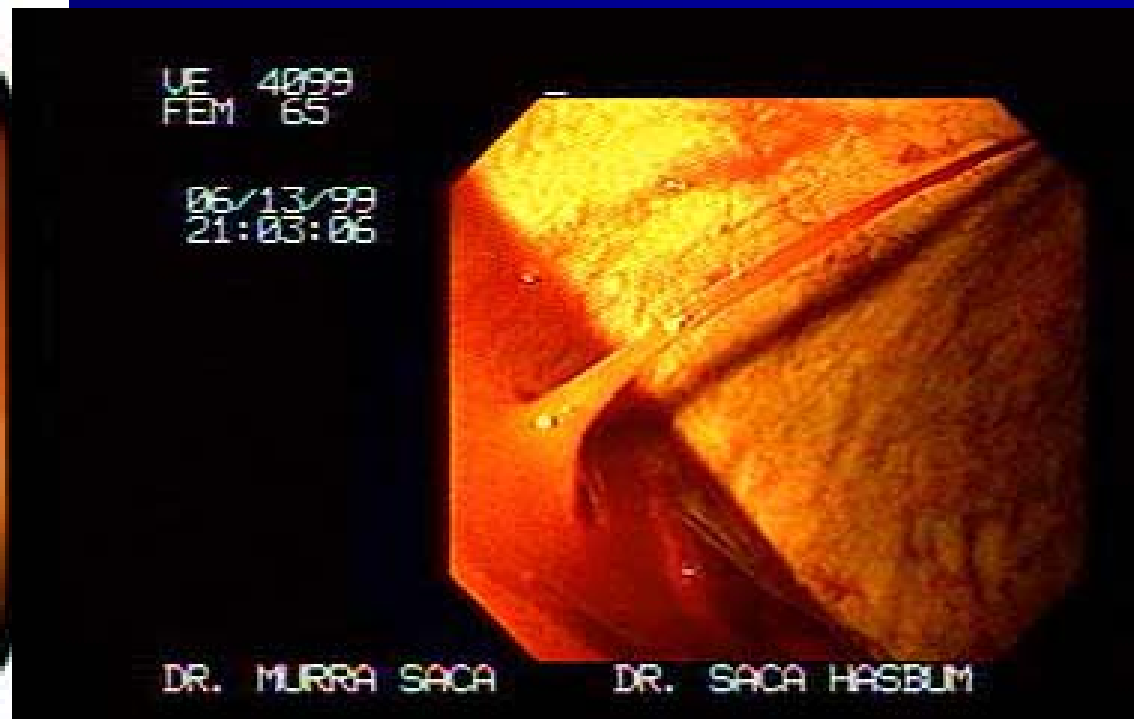
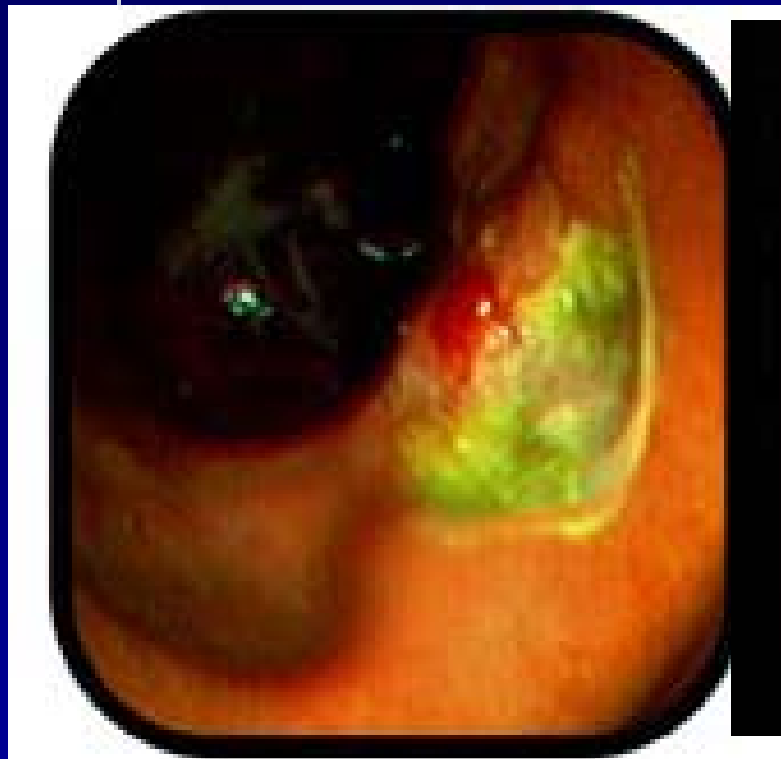Esophageal Varices



Banding Devices



Peptic Ulcer bleeding

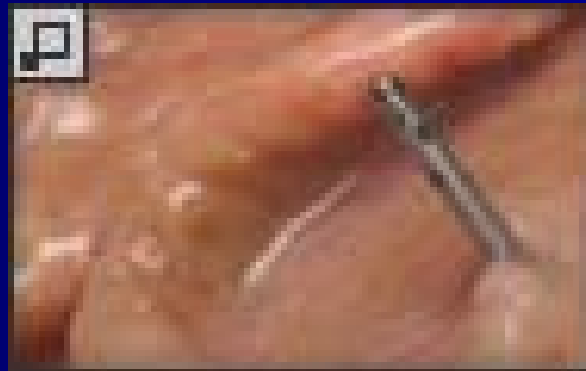



Injection sclerotherapy & Heater probe



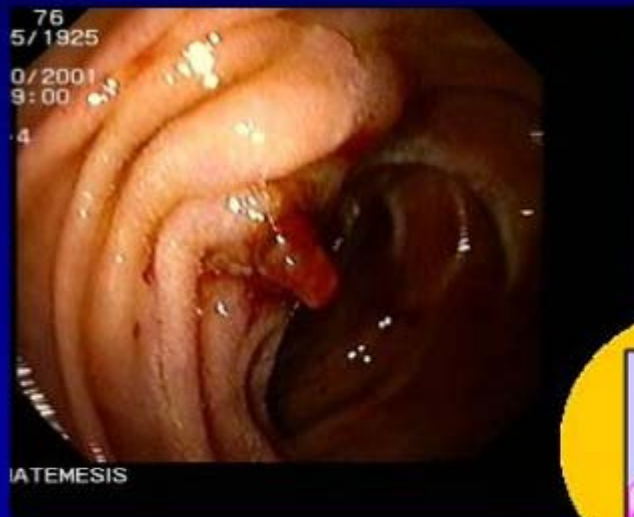Endoclips / Haemoclips



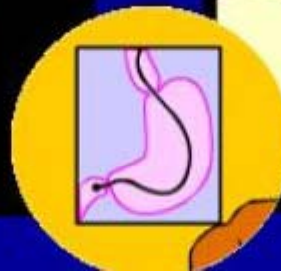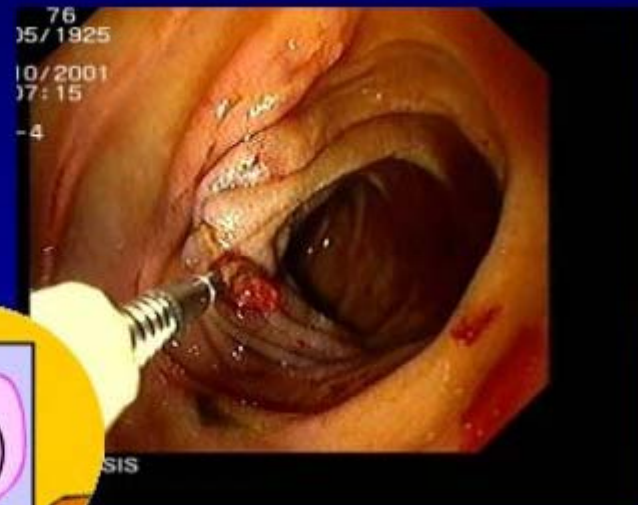


Clipping a Duodenal Ulcer

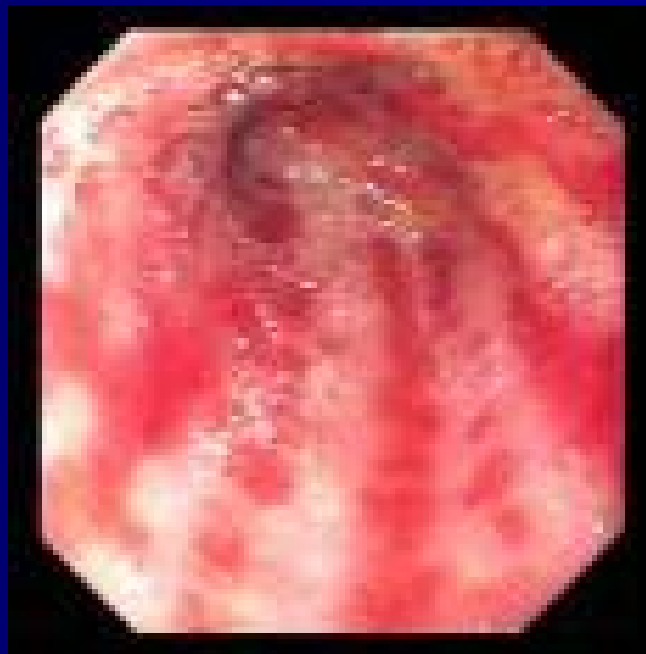Peering through the pylorus into the duodenum, we see some blood and a vessel sticking out of the wall, just at the front edge of a small but deep ulcer.

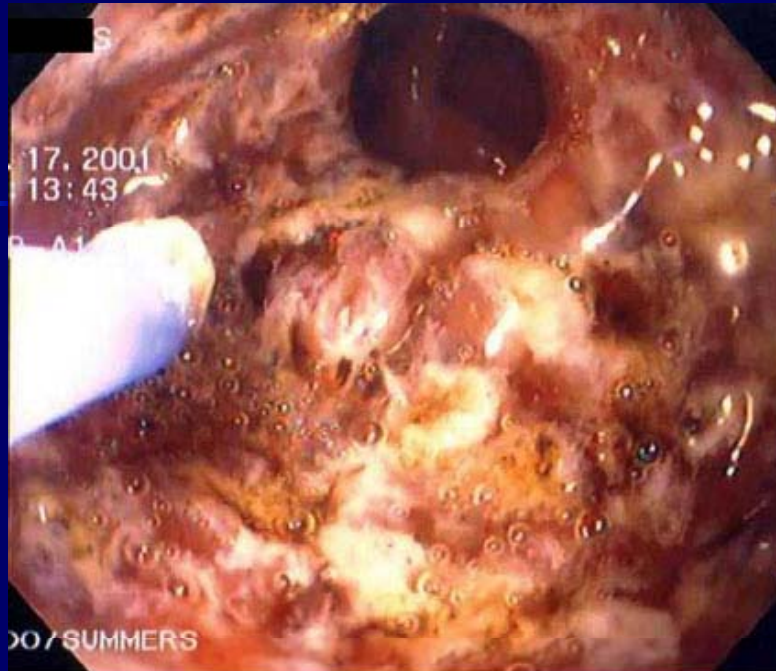

In the second photograph, a disposable metal clip is applied to the ulcer. The patient remained well and left hospital three days later.

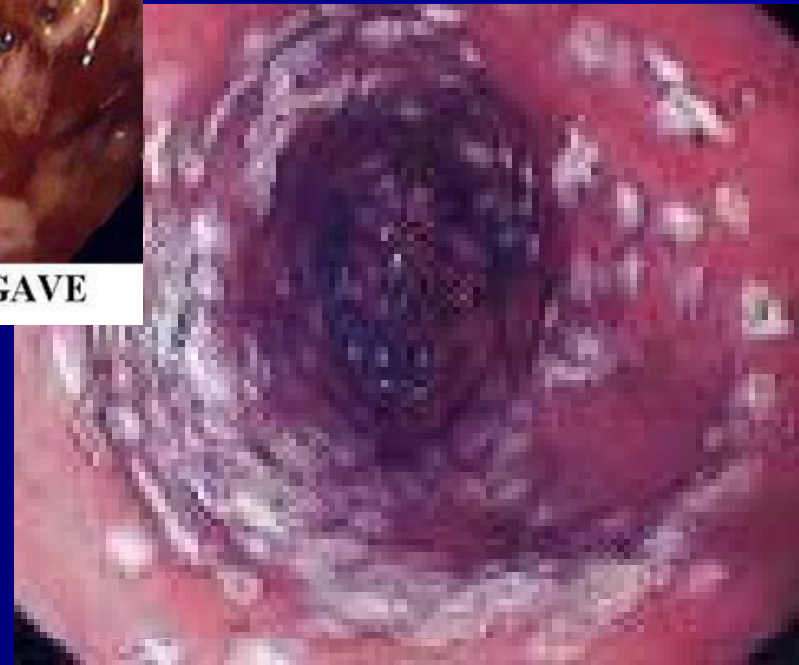


Gastric Antral Vascular Ectasia

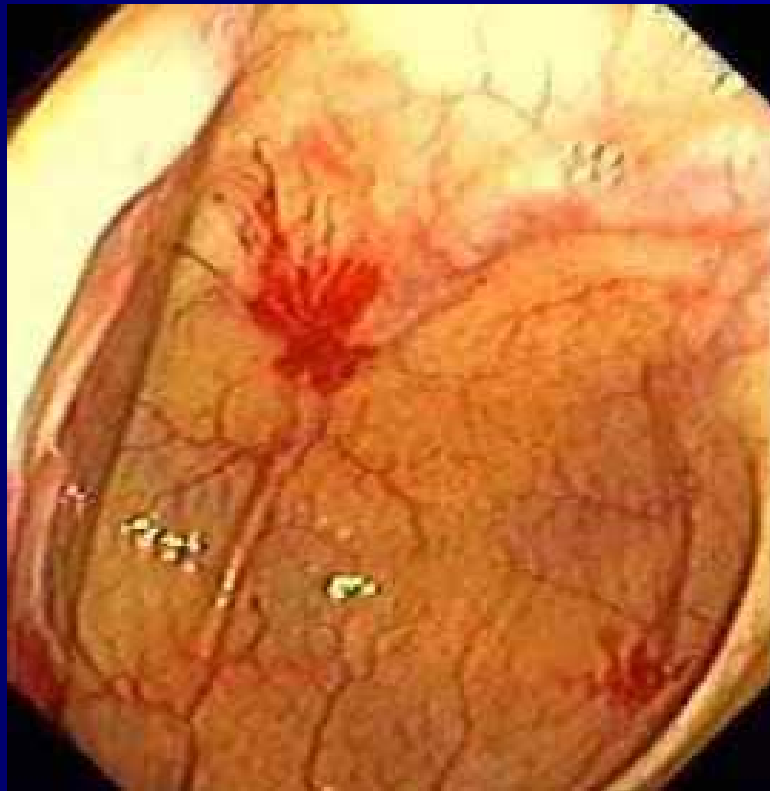




Argon plasma coagulator therapy of GAVE

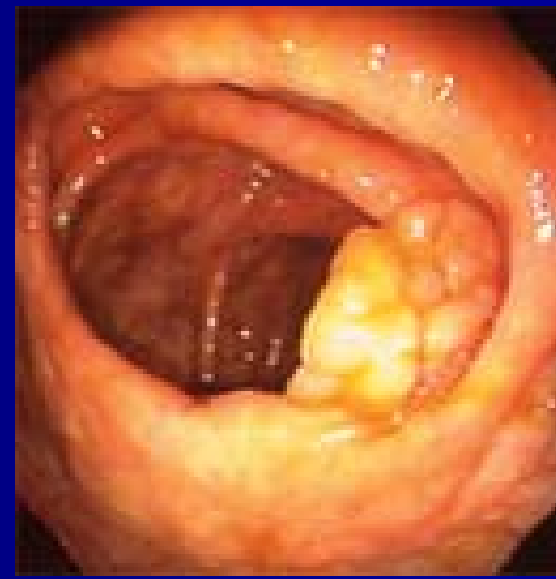
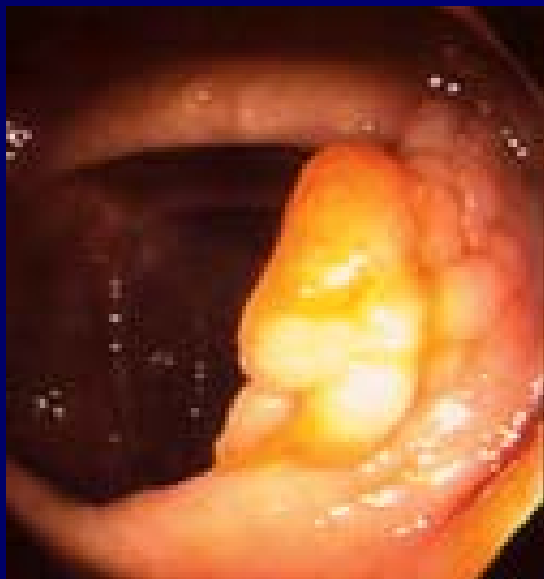
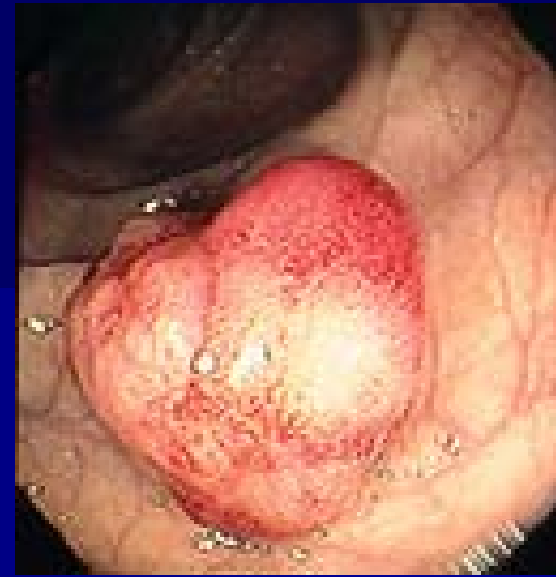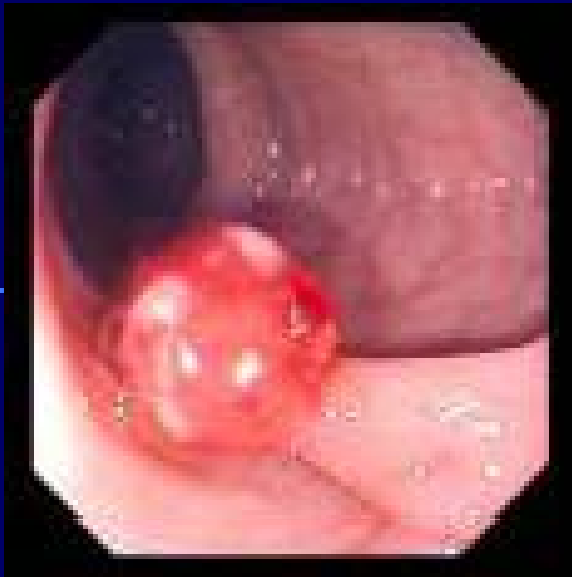Angiodysplasia



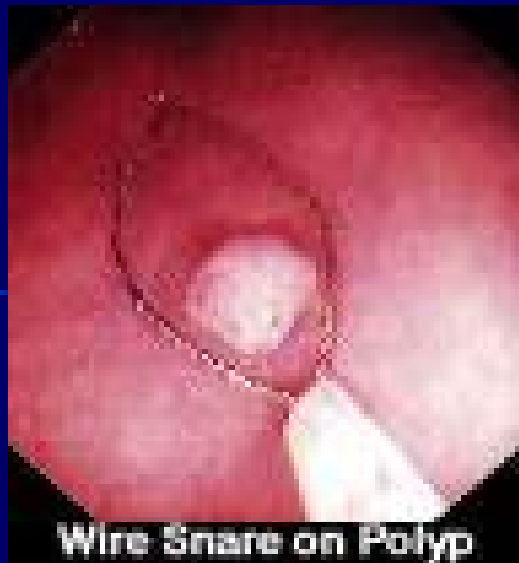Endoscopic management of GI neoplasia

- Polypectomy
 - +/- submucosal injection
- Endomucosal resection
- Stenting
- (Laser)
- (Ethanol injection)

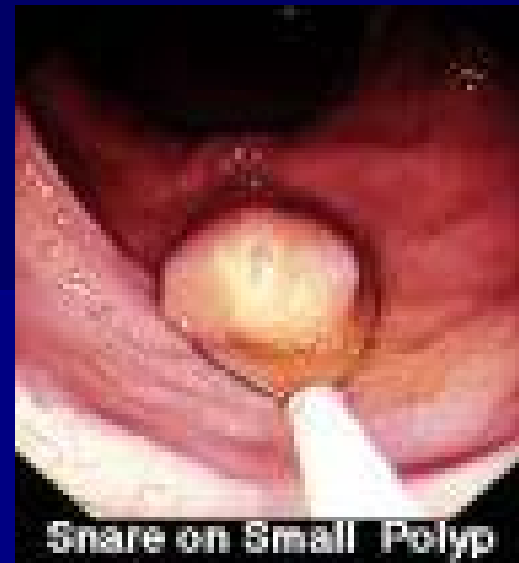

Polypectomy snare

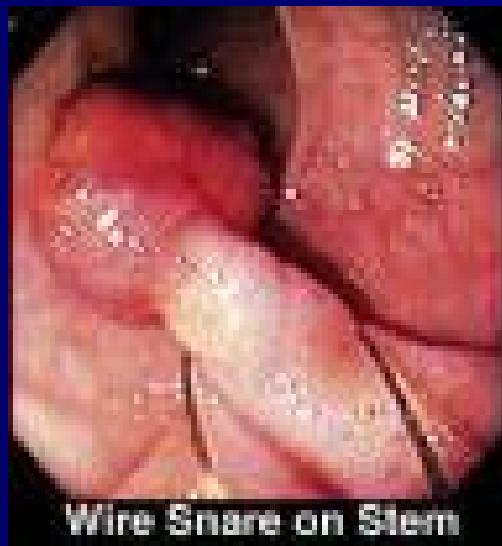



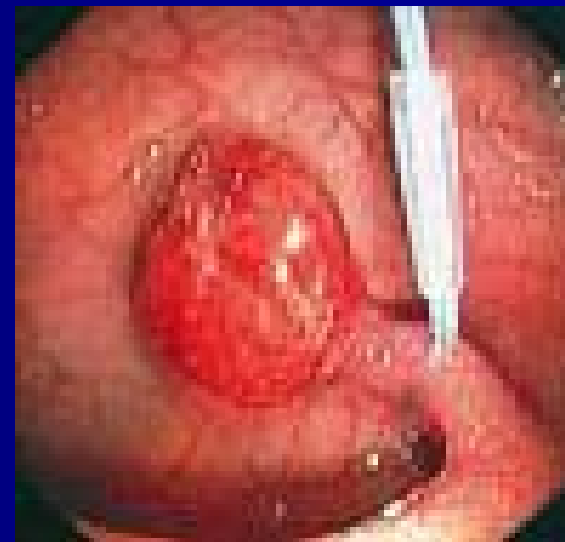
Wire Snare on Polyp

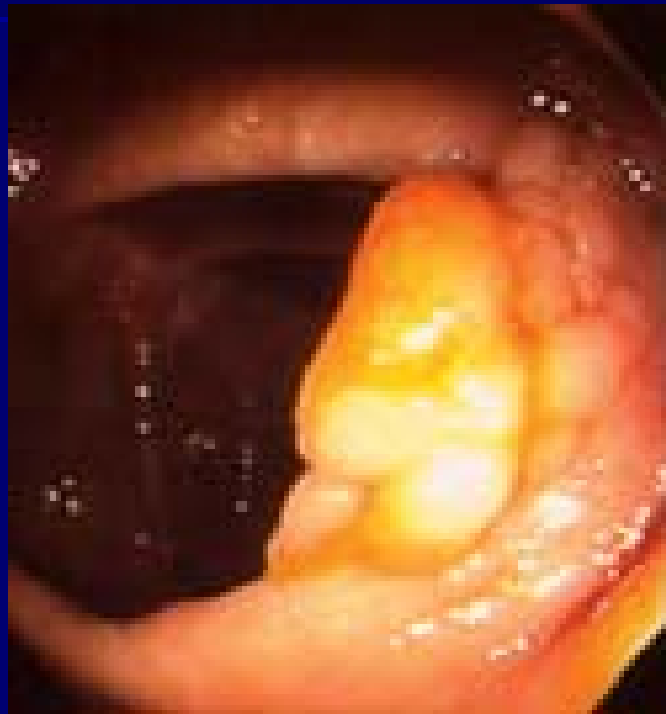

Snare on Small Polyp

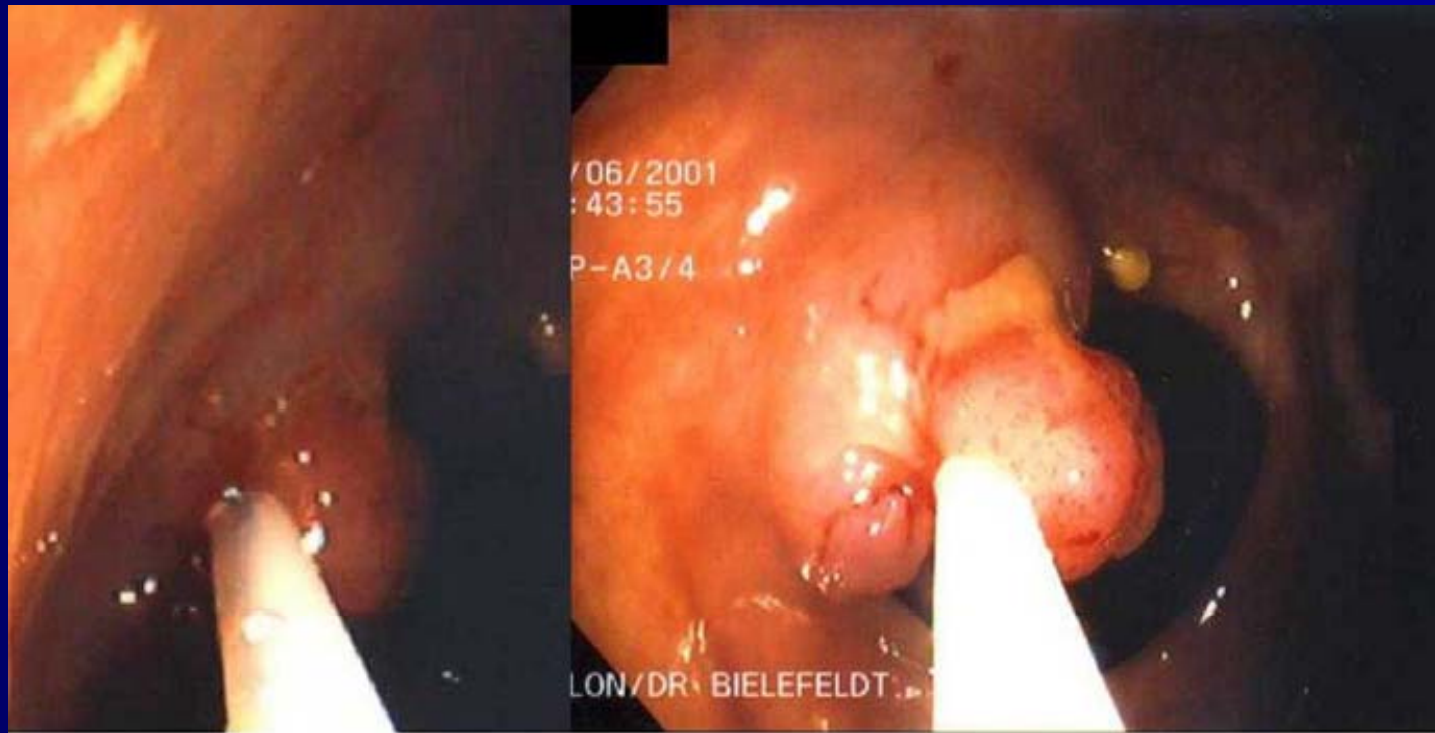


Wire Snare on Stem



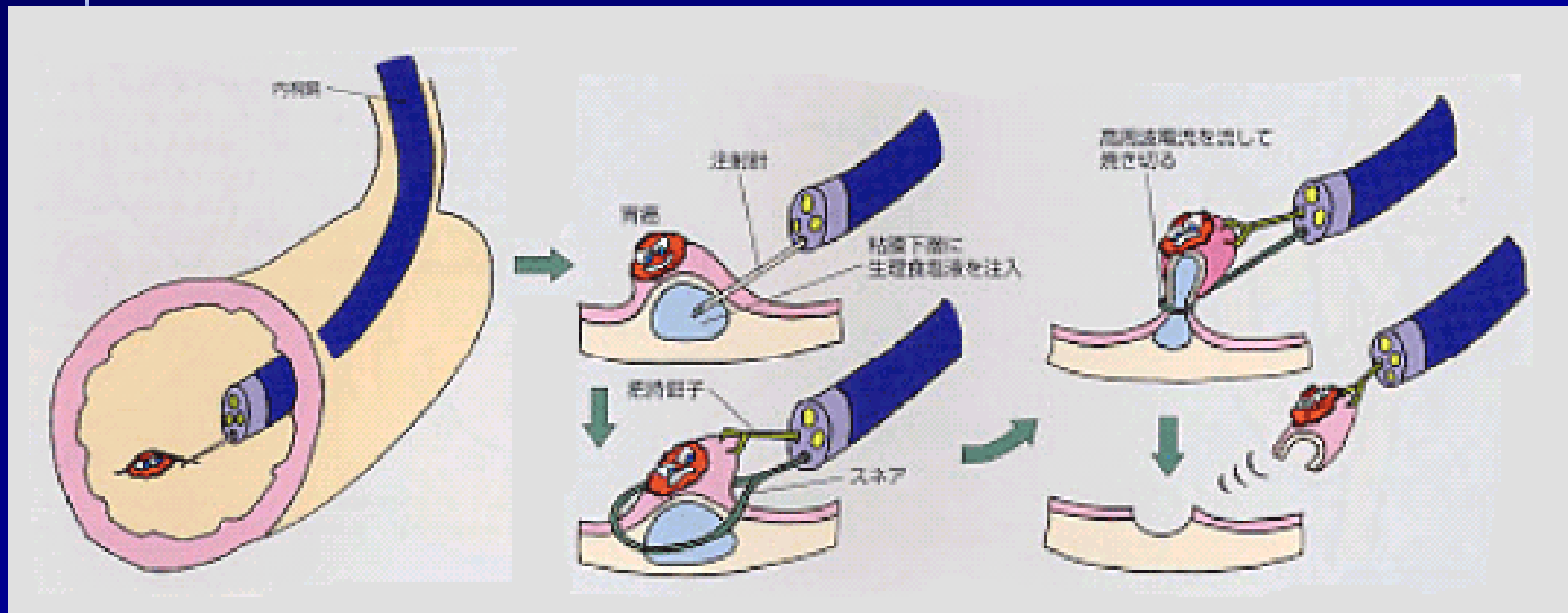


Polypectomy with submucosal injection

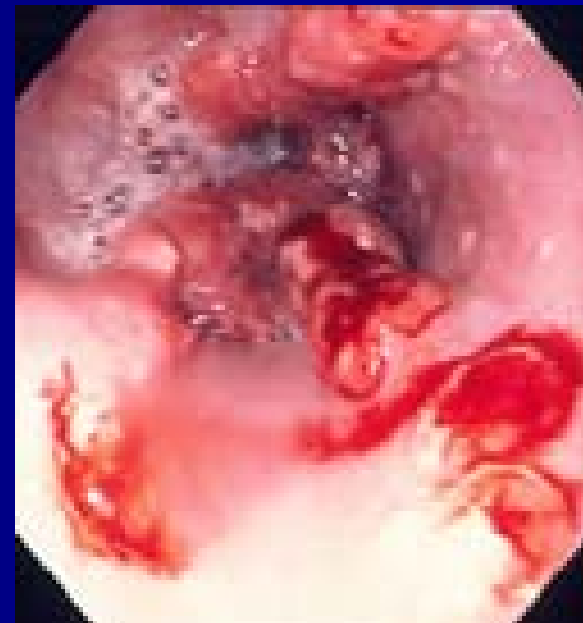
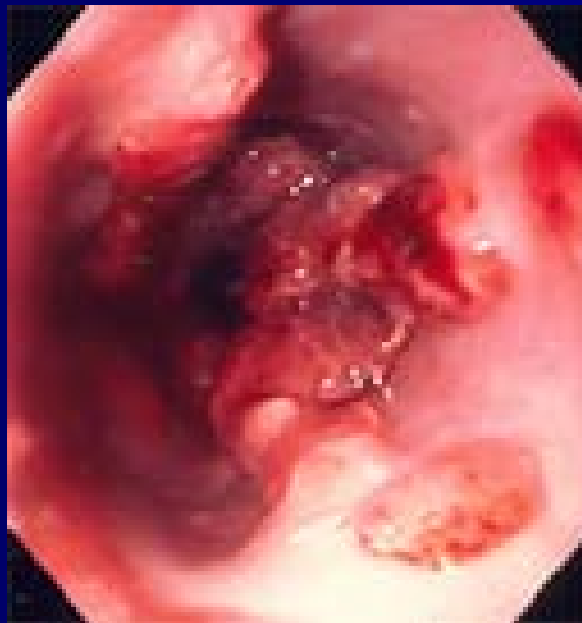
Snare polypectomy after submucosal saline injection

Endomucosal resection

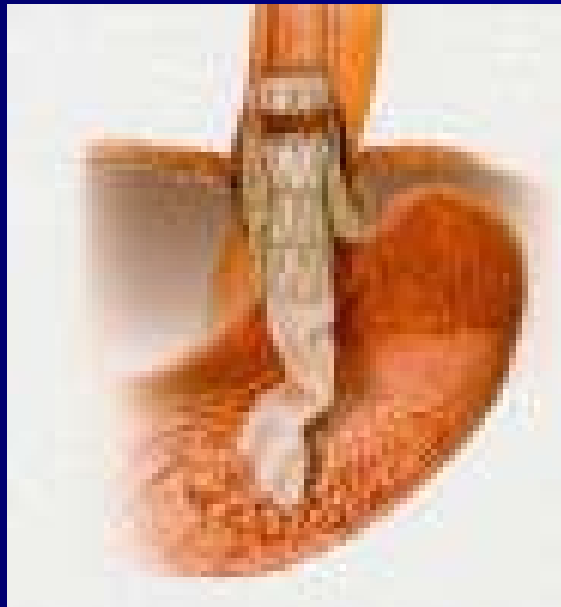


Obstructing Esophageal Malignancy

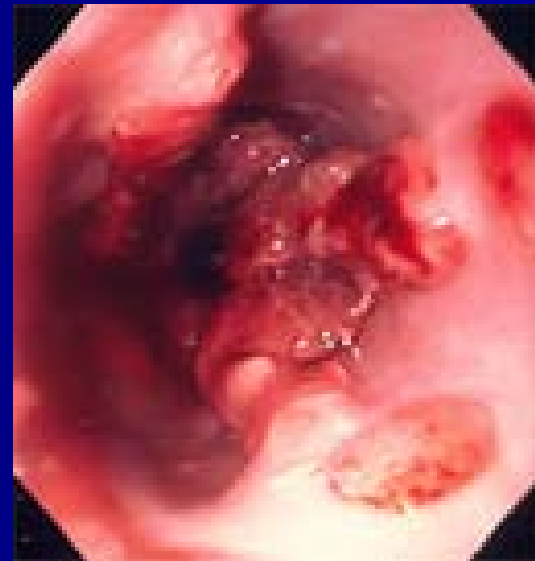
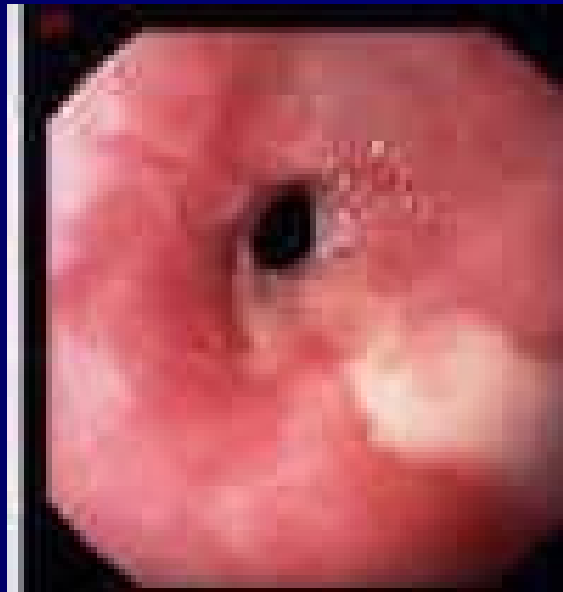
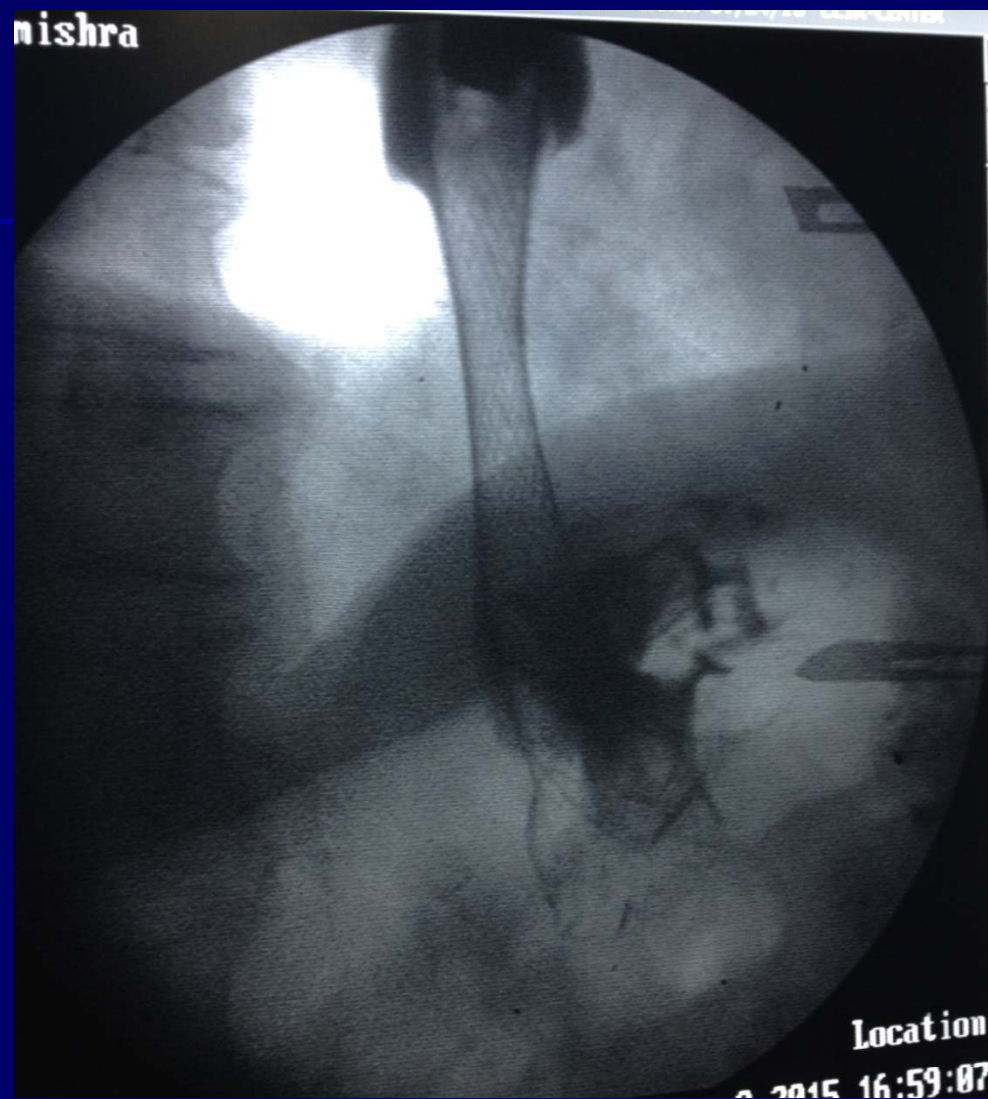
Esophageal stents





Esophageal strictures



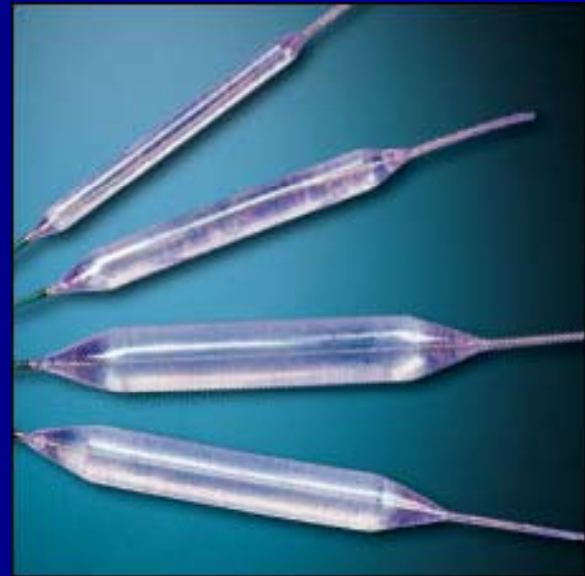

nishra

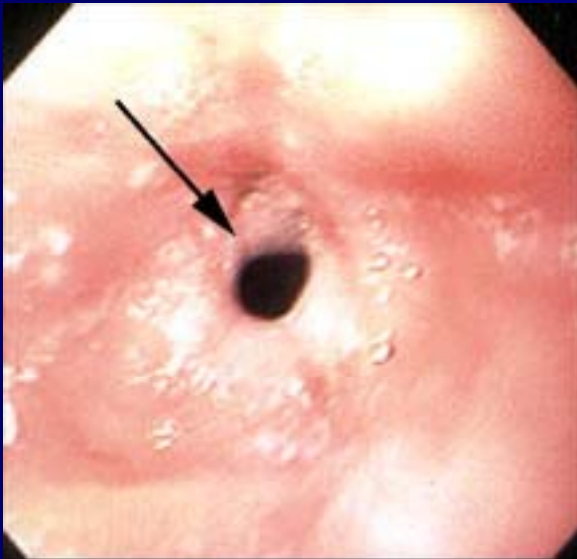
Location

2015 16:59:07

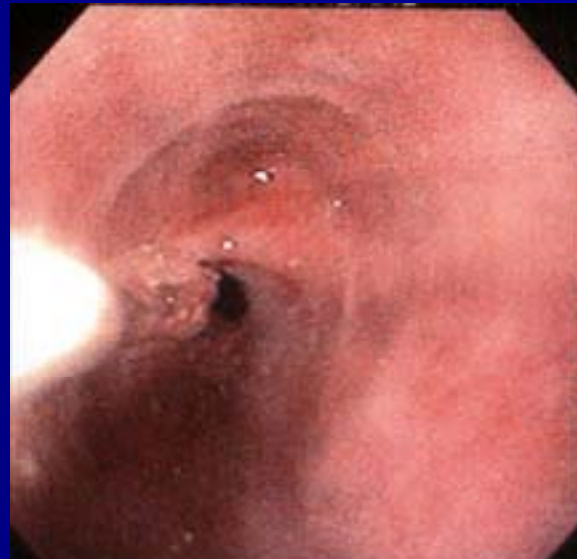Esophageal dilators



Balloon dilatation

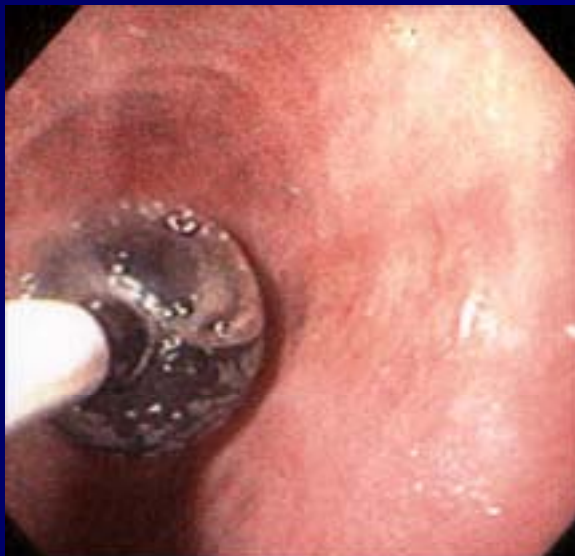


Narrow esophageal stricture

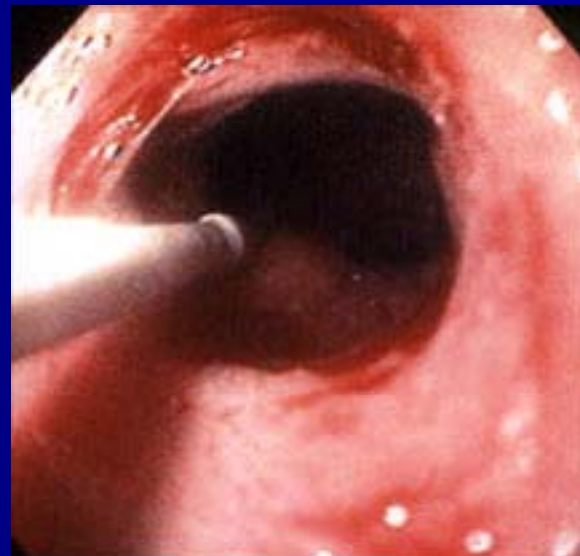


Placing balloon dilator

Balloon dilatation (cont)

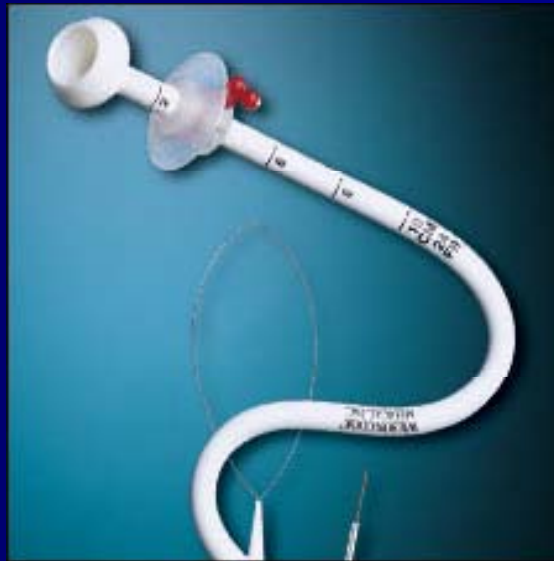

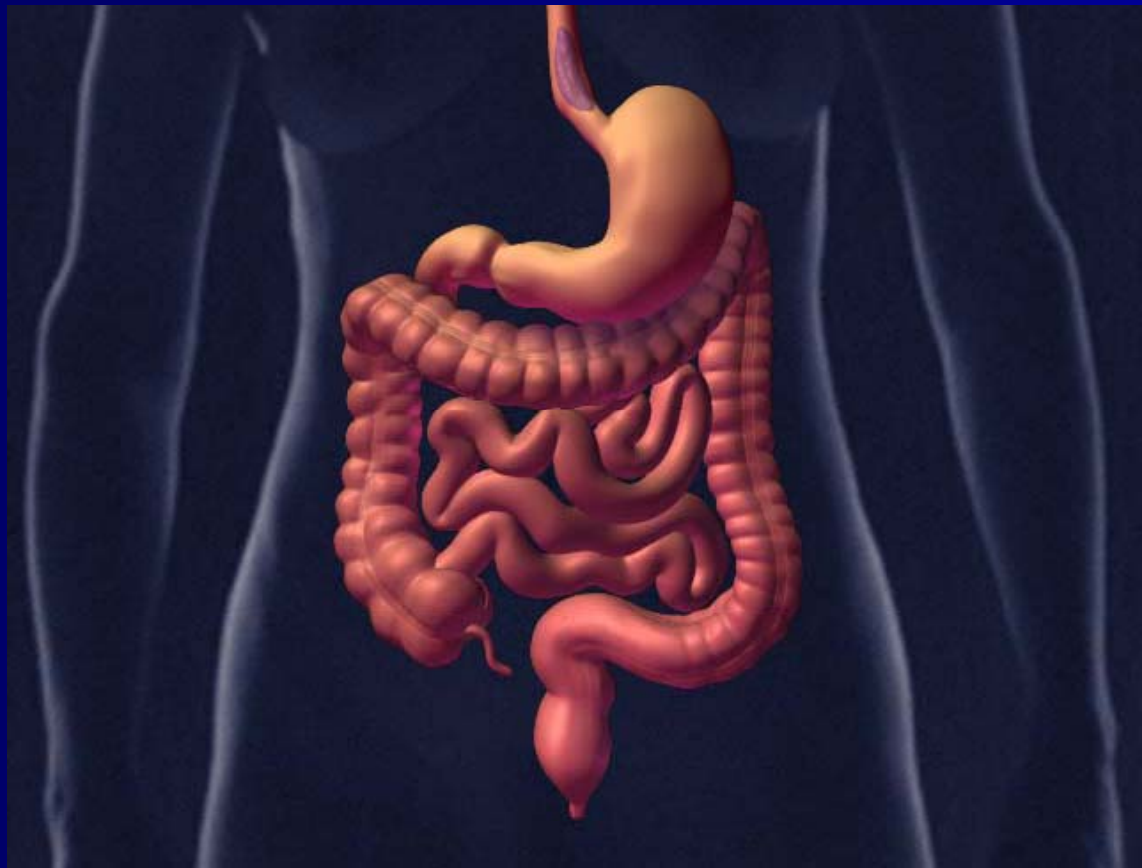Inflated balloon dilator

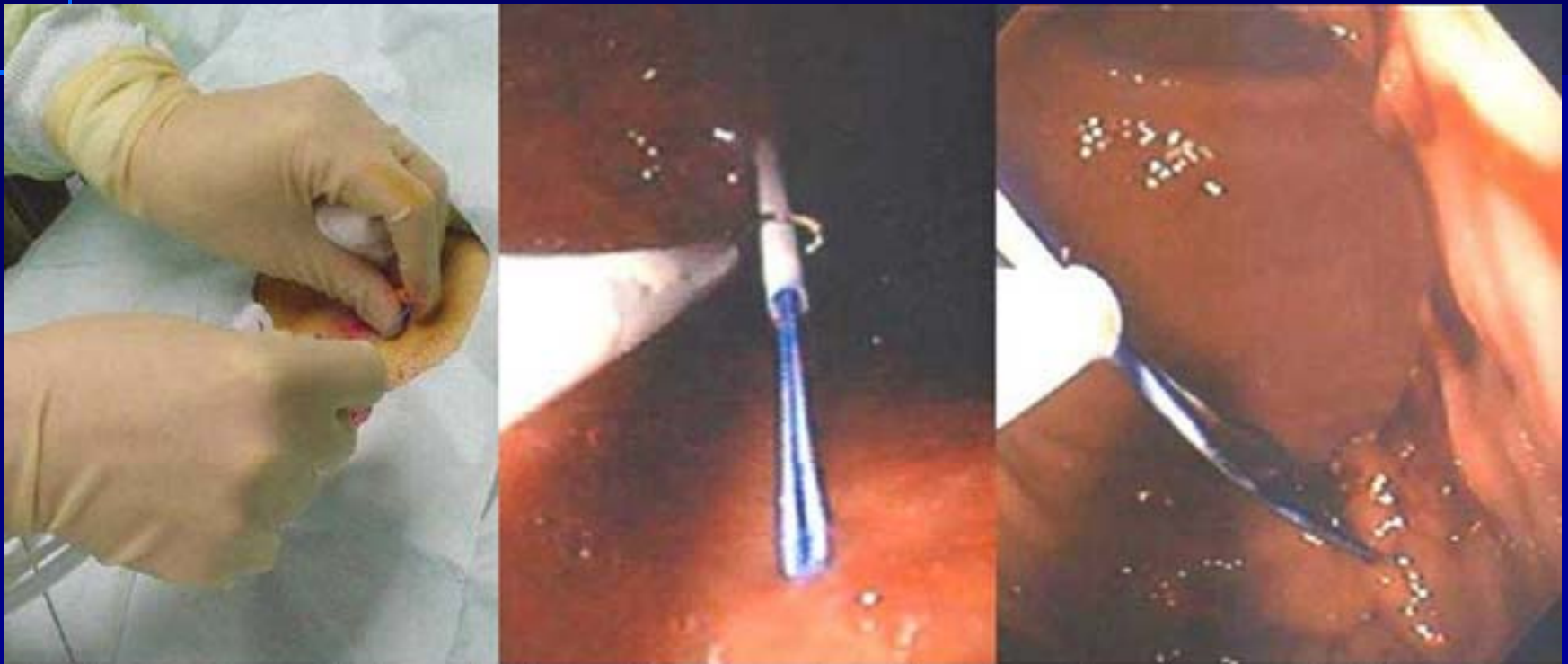


After balloon dilation

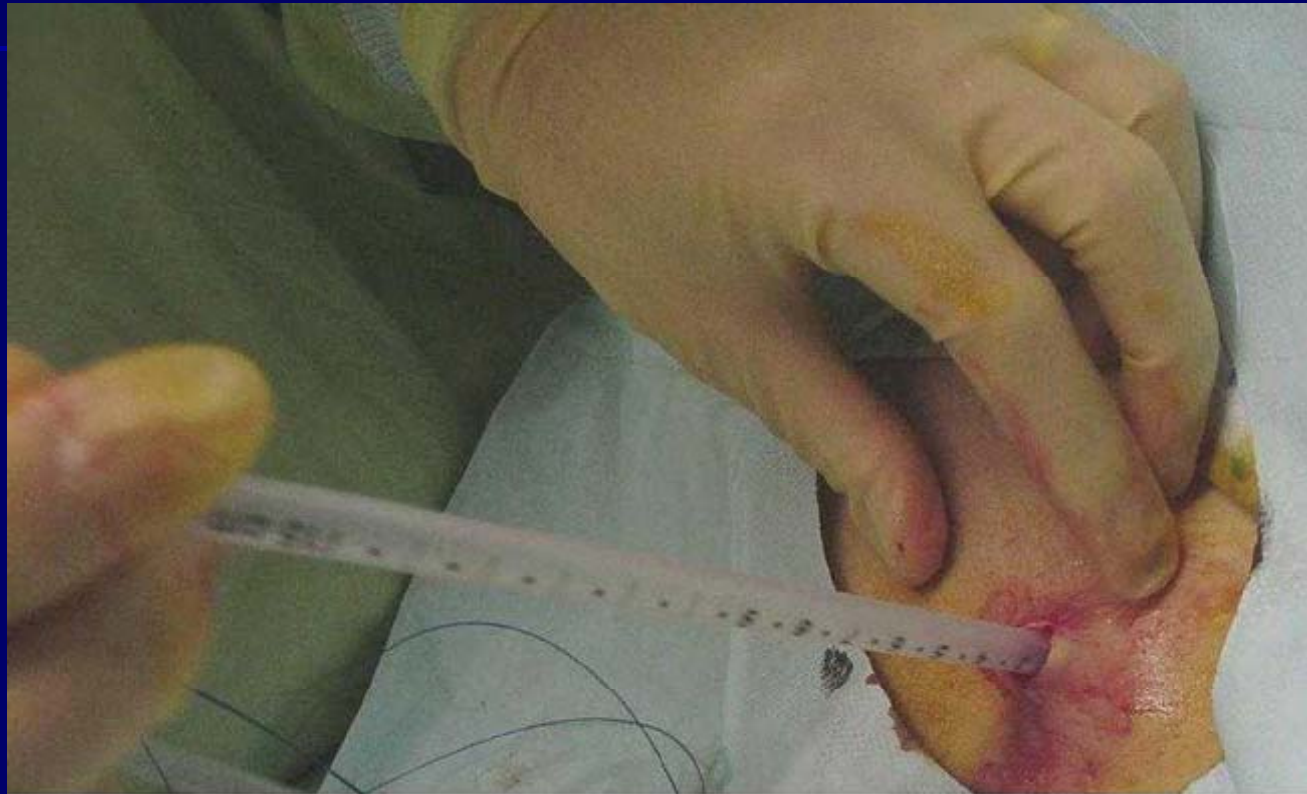Percutaneous gastrostomy (PEG)



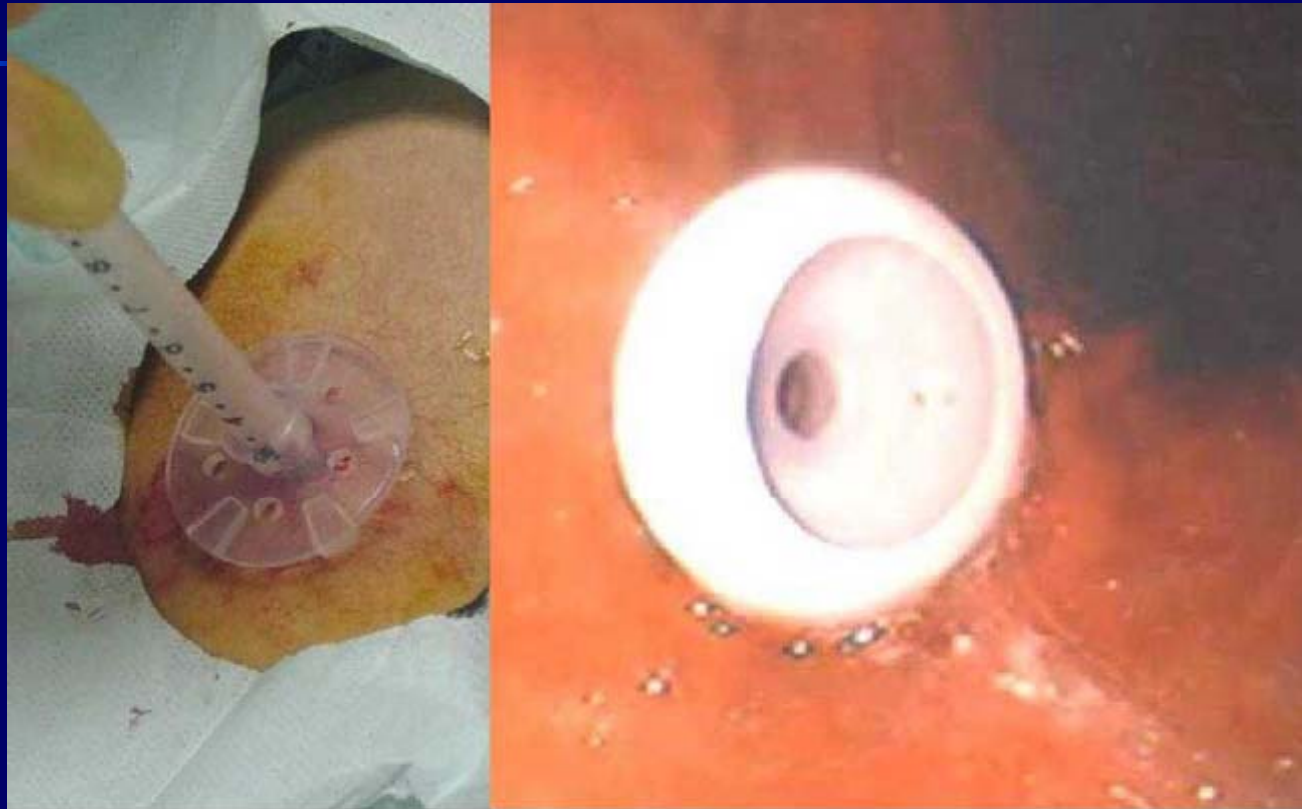




A wire is advanced through the angiocatheter into the stomach and grasped with a snare.



Gastrostomy tube is pulled through the previously identified site.

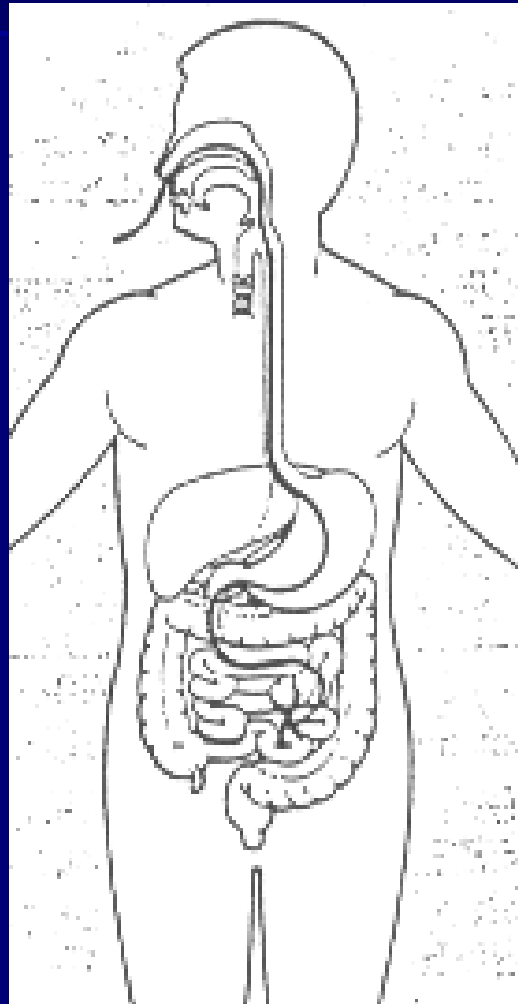


Gastrostomy tube in place with ring and button positioned properly.

Percutaneous gastrostomy: low profile device



Nasojejunal feeding tube

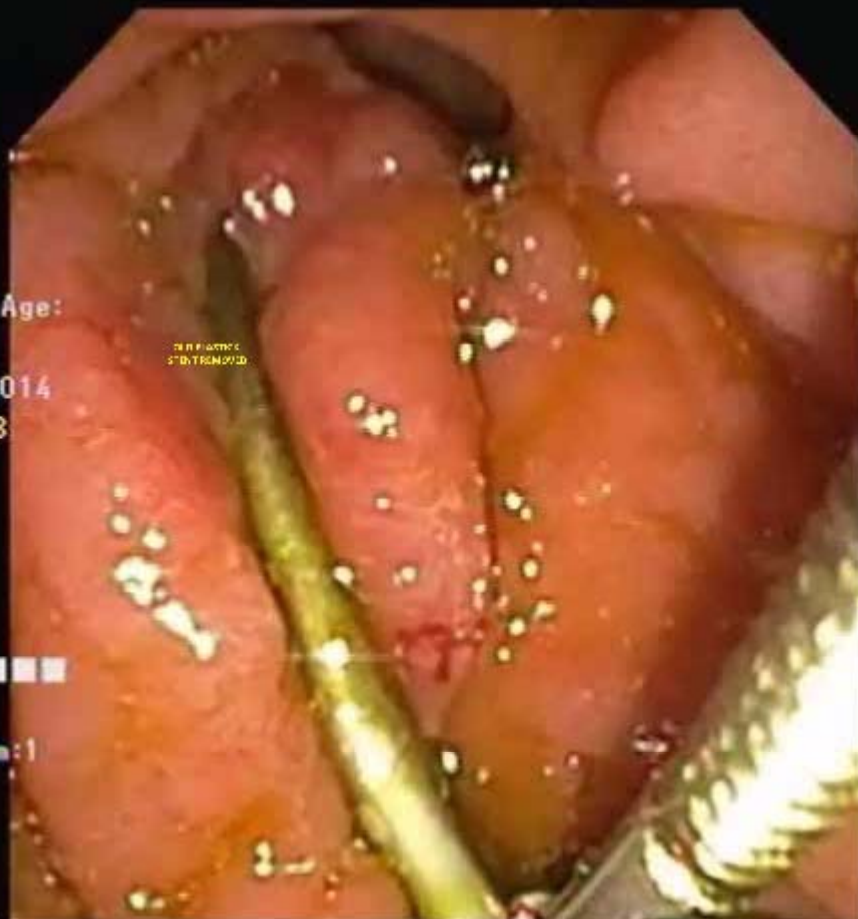

**Distal Cholangiocarcinoma
palliative stenting for obstructive jaundice
in a 80 plus female.**

ID:
Name:

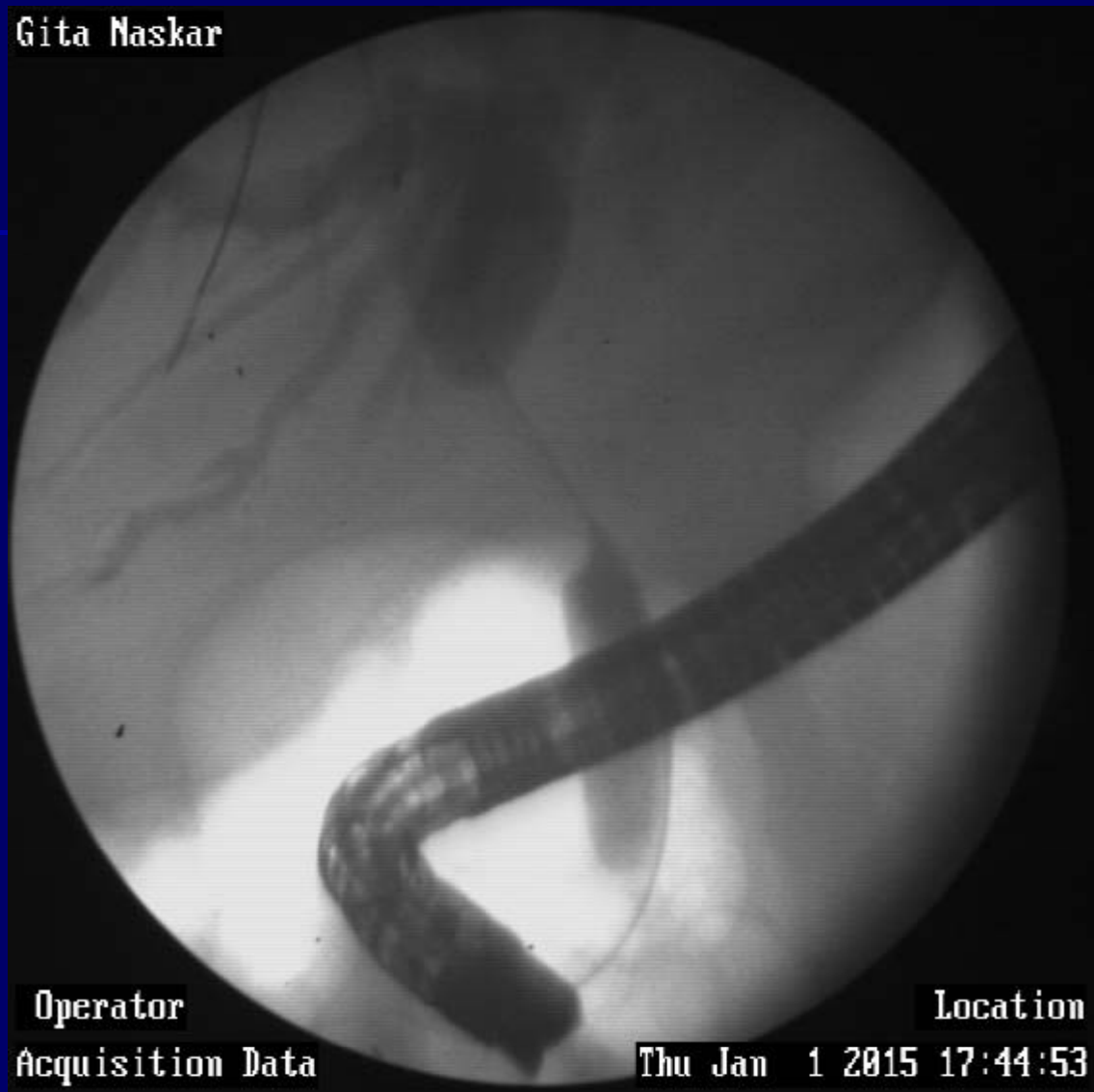Sex: Age:
D.O.B.:
11/11/2014
10:53:08

■■■■/■■■■
0/1
Eh:A3 Cm:1



**Ca GB with proximal CBD
infiltration in a 70 years female**

Gita Naskar

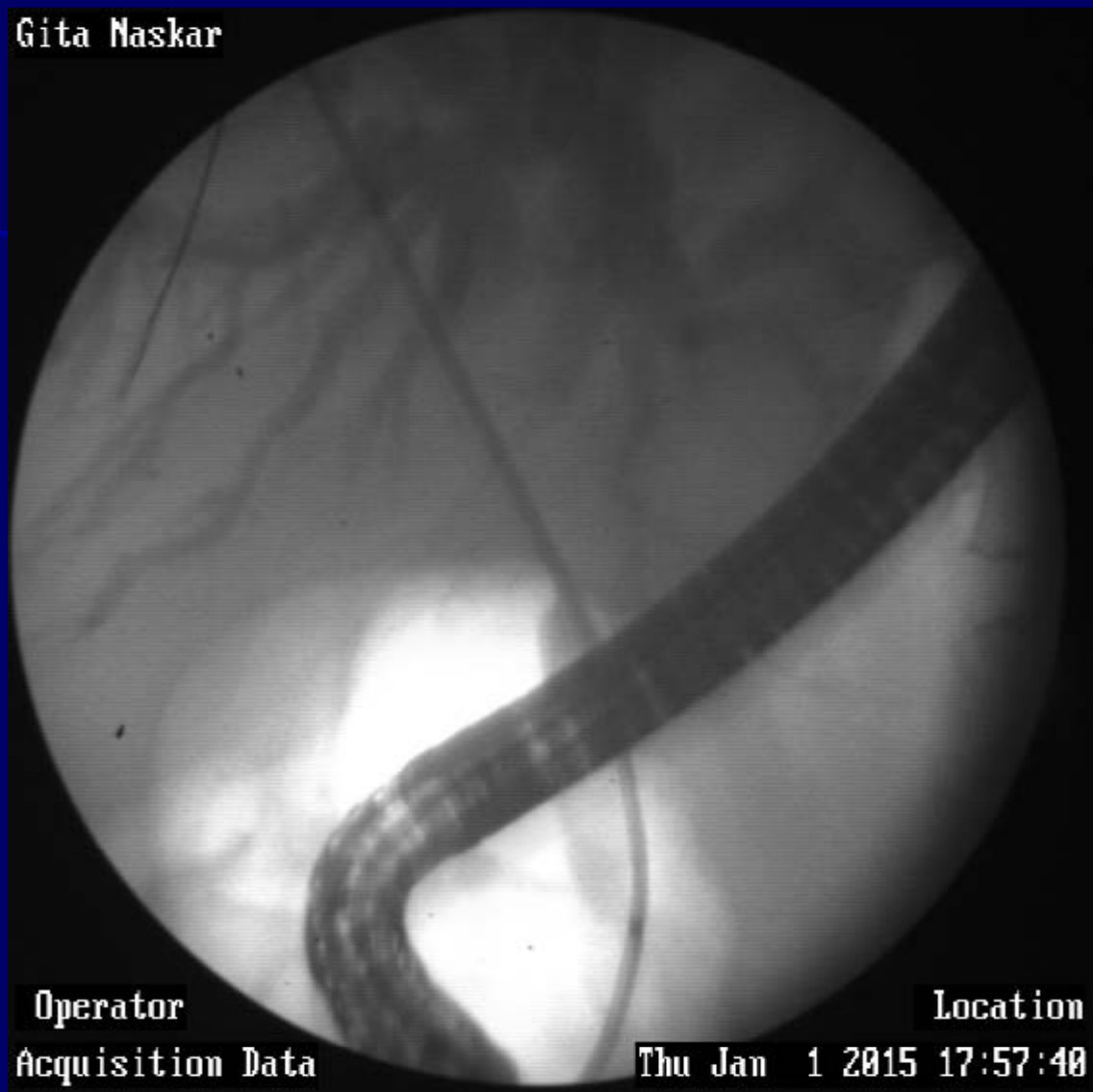

Operator
Acquisition Data

Location

Thu Jan 1 2015 17:44:53

Gita Maskar

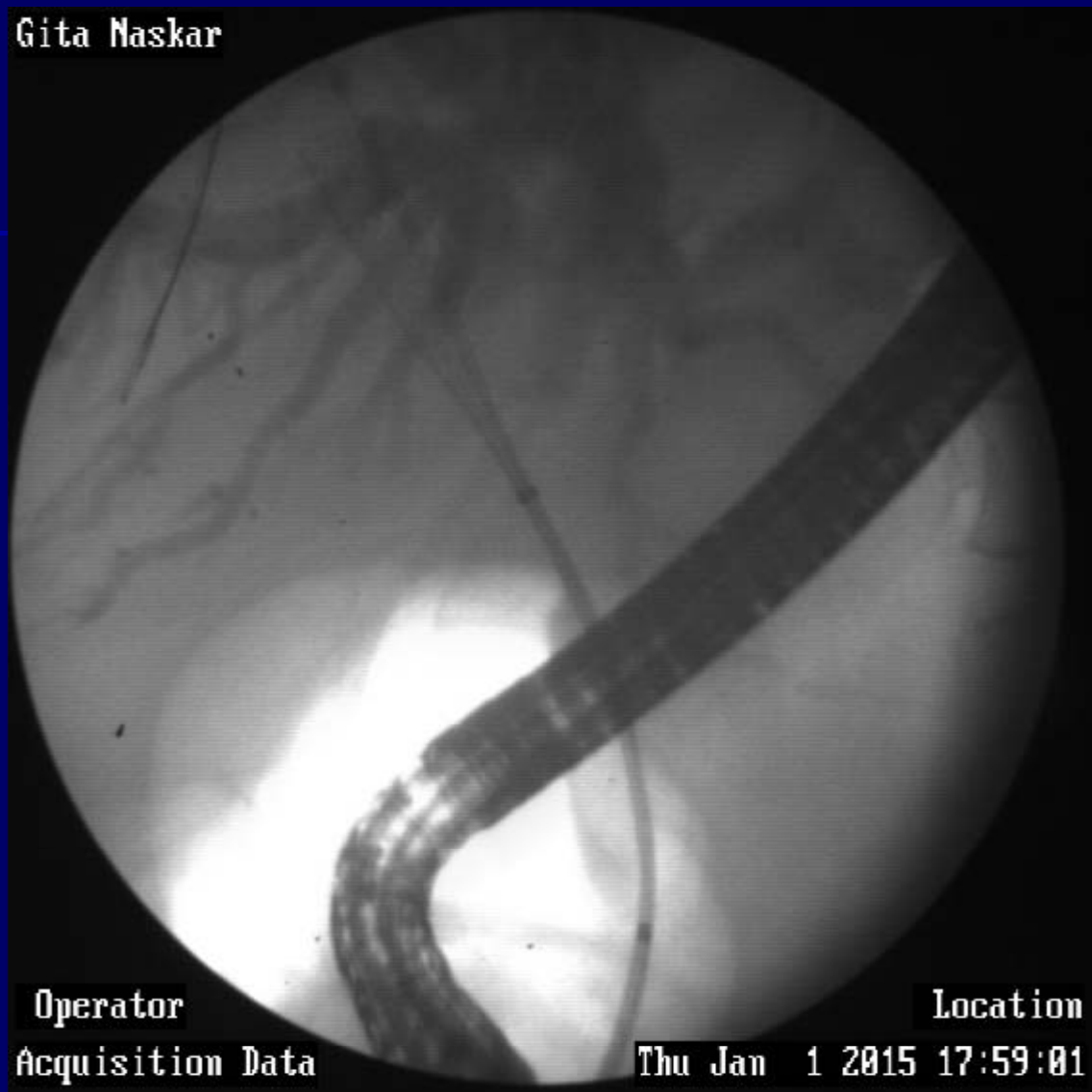

Operator
Acquisition Data

Location

Thu Jan 1 2015 17:57:40

Gita Naskar

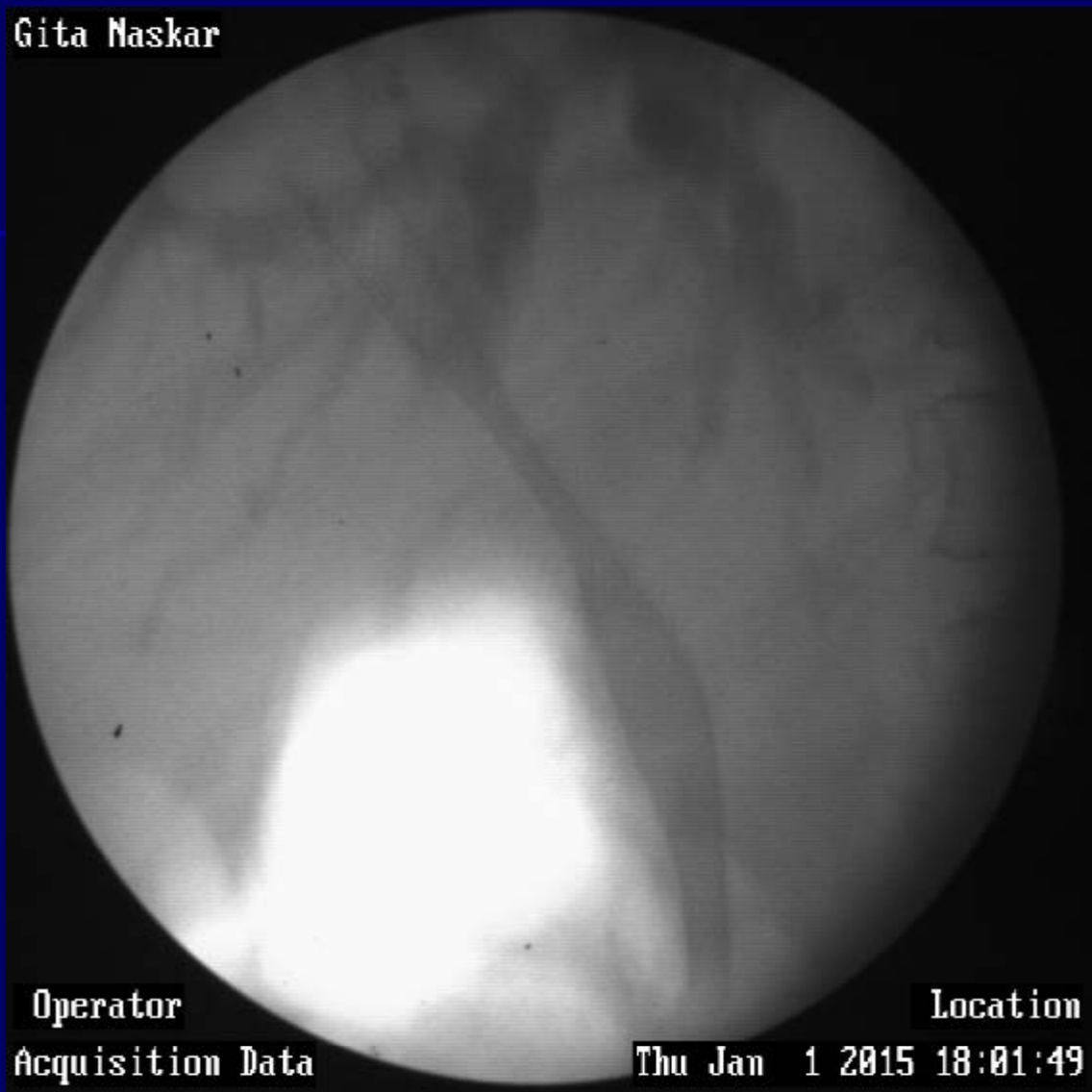

Operator
Acquisition Data

Location

Thu Jan 1 2015 17:59:01

Gita Maskar



Operator
Acquisition Data

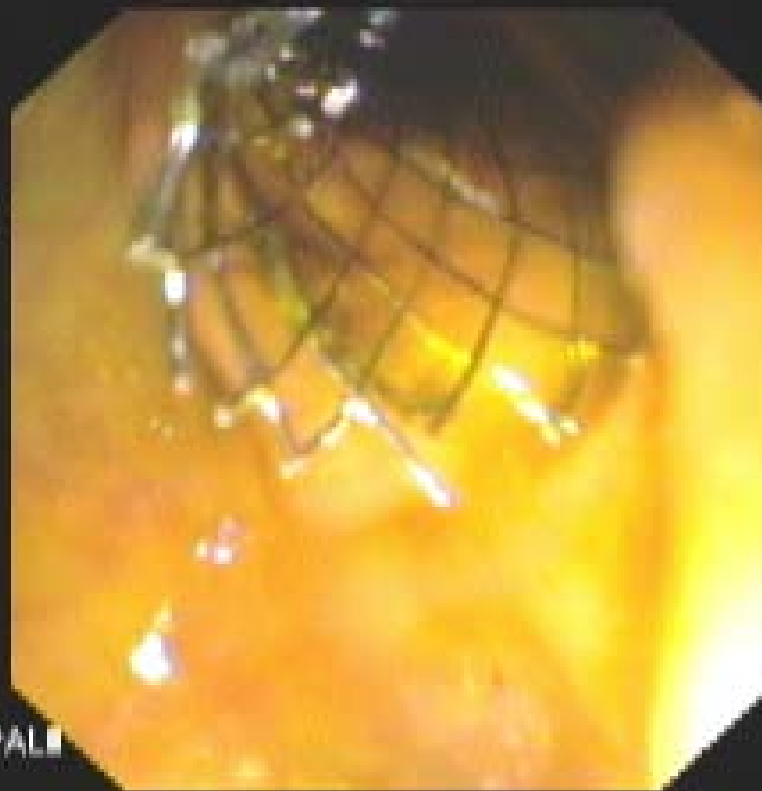Location

Thu Jan 1 2015 18:01:49


21/08/2014
20:10:00

CVP:
D.FI
bL

F.N.C.P.
DR. GANDIP PALI



Choledocholithiasis with benign CBD stricture Post Cholecystectomy

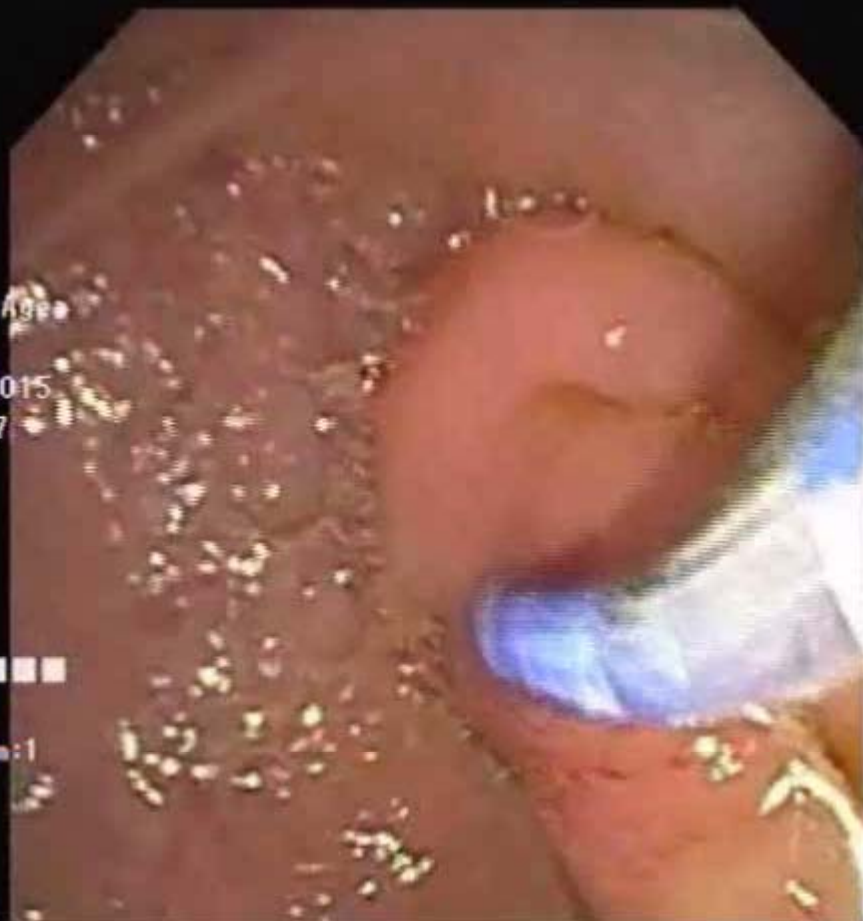


**18 years with chronic calcific
pancreatitis and obstructive
jaundice due to inflammatory
stricture of distal CBD**


ID:|
Name:

Sex: Male
D.O.B.:
12/01/2015
10:12:37

■■■■/■■■■
0/1
Eh:A3 Cm:1



**50 years female patient
Periampullary malignancy with
cholangitis and obstructive
jaundice**





TIPSS

Indications for TIPS

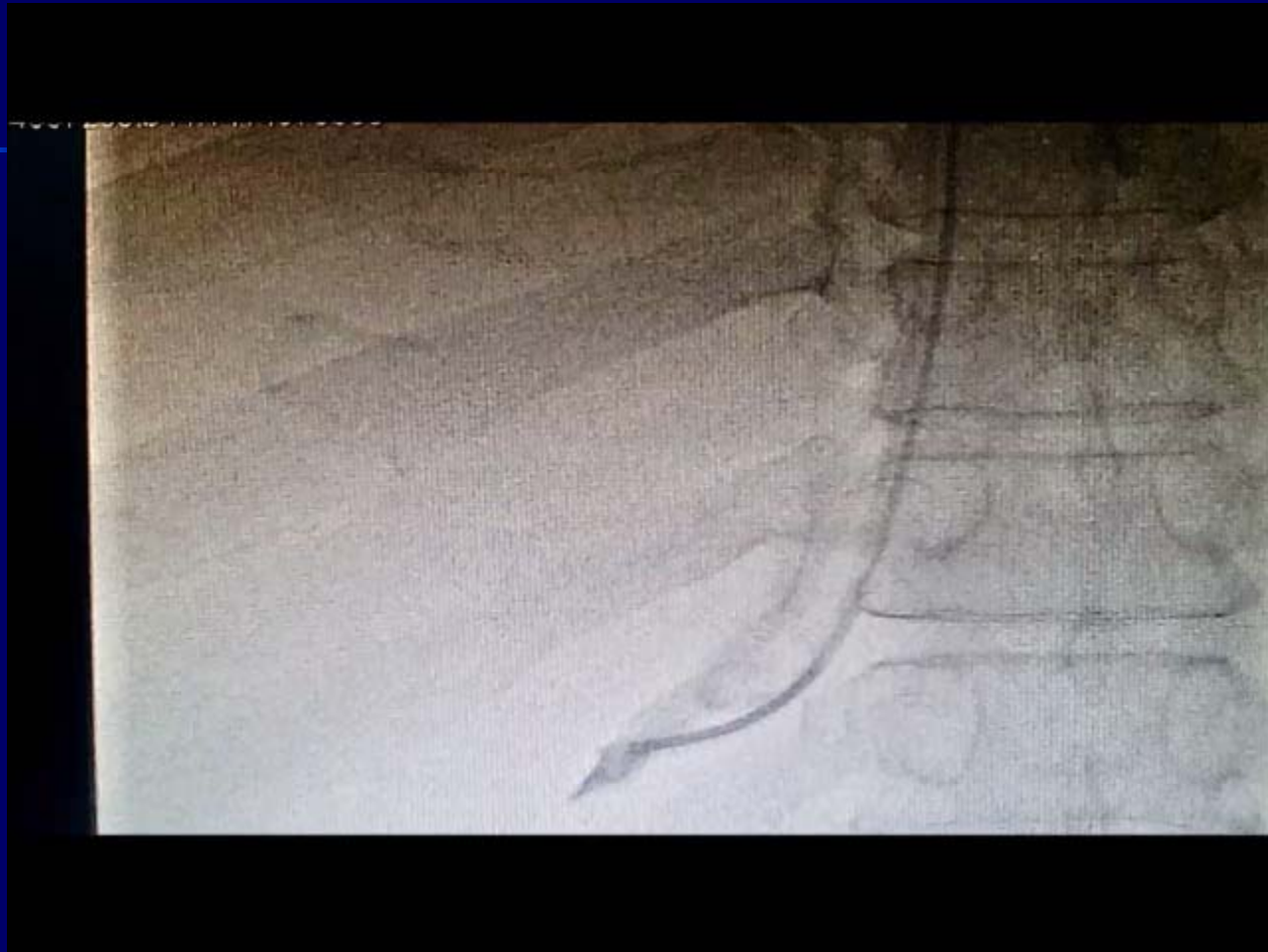
Efficacy Determined by Controlled Trials

Secondary prevention variceal bleeding
Refractory cirrhotic ascites

Efficacy Assessed in Uncontrolled Series

Refractory acutely bleeding varices
Portal hypertensive gastropathy
Bleeding gastric varices
Gastric antral vascular ectasia
Refractory hepatic hydrothorax
Hepatorenal syndrome (type 1 or
type 2)
Budd-Chiari syndrome
Veno-occlusive disease
Hepatopulmonary syndrome

(Hepatology Feb 2005)



Endoscopic Cystogastrostomy
Ac pancreatitis with a large
pseudocyst in a 24 years
alcoholic patient

Pat Name: SHIT MADHUSUDAN

Pat ID: 17510000423363

Pat DOB: 28-10-1989

Pat Sex: M

Pat Age: 25Y 1M

Modality: CT

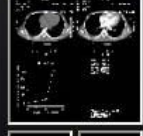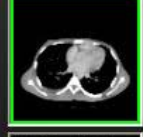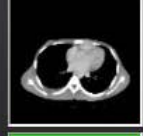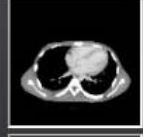
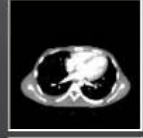
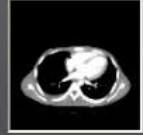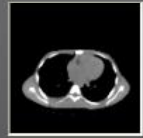
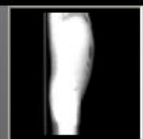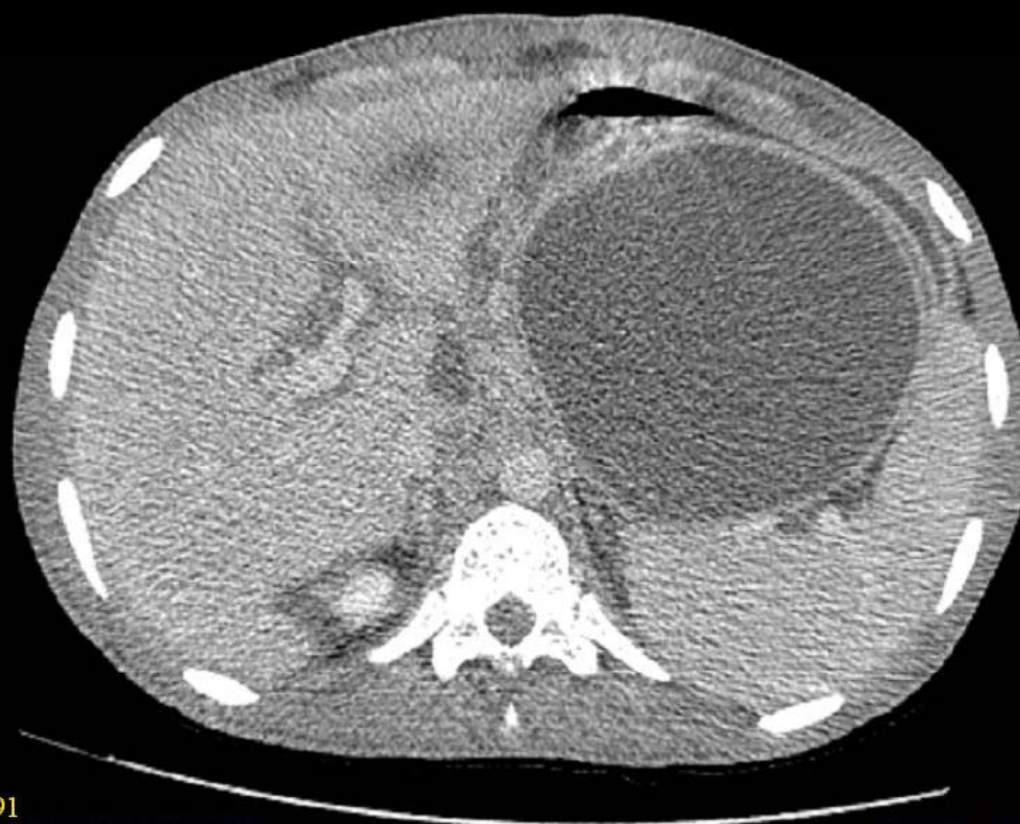Study: 1

Series: 7/10

Image No: 167/441

Slice Location: -46.750

Slice Thickness: 0.625000

Sync: ☐0
5
10
15

Acc No: ICCT14006991

Study Desc: CT PANCREAS DUAL PHASE

Date: 29-10-2014

Time: 19:42:53

Series Desc: THIN

Select: ☐


Inst Name: R.T.I.L.C.S., KOLKATA

WW: 400

WL: 40

Exp Time: 400 ms







THANKS